

Investigation of the Anti-Inflammatory Potential of A Methanolic Extract of Ackee Leaf (*Blighia Sapida*) on Rheumatoid Arthritis (Complete Freund's Adjuvant (CFA) Model) and Acute Toxicity Profile

K Reid¹, AS Jacob^{1*} and AS Levy²

¹Department of Basic Medical Sciences, University of the West Indies, Pharmacology and Pharmacy Section

²Nova Southeastern University, College of Medical Sciences, USA

Volume 1 Issue 1 - 2018

Received Date: 18 June 2018

Accepted Date: 08 July 2018

Published Date: 12 July 2018

2. Keywords

Ackee leaf extract; Adjuvant Arthritis; Leucocytes; Cartila

1. Abstract

1. Introduction: Rheumatoid Arthritis is an autoimmune disease that affects the joints. Females older than forty years of age are more susceptible. Complete Freund's adjuvant induced joint inflammation in male rats. A methanol extract was tested for anti-inflammatory effects on joints.

1.2. Method: Twenty four rats were used. Rats from Group 1 were given Diclofenac 25mg/ml, group 2 rats were given 120mg/ml of ackee leaf extract and rats from group 3 were given 0.2ml of saline via oral gavage. Group 4 rats were untreated. 0.5ml of CFA (containing 1mg/mL of heat-killed mycobacterium) was injected thirty minutes post treatments into the synovial cavity of the left knee. At day 28 all treated animals animal were sacrificed. Blood was taken for hematology studies and joints for histology assessment.

1.3. Results: Diclofenac caused the greatest reduction in swelling of the knee joints of the rats (p value <0.001). The methanol extract of ackee leaf also reduced swelling in the knee joints (p value < 0.001). In both test groups the total leukocyte counts were not significant (p .> 0.05).

In histology studies, cartilage degradation in the extract group were not as Ainvasive as that of saline controls. Acute toxicity testing confirmed that the extract is not toxic at a 2000 mg/kg.

1.4. Conclusion: Ackee leaf extract reduces swelling of the knee joints, with no significant increase in white blood cell count at this site and gives some protection to cartilage integrity. Ackee leaf extract appears to be non-toxic at a dose of 2000 mg/ kg. Isolation of the bioactive compound can be done to assess for further efficacy.

3. Introduction

Rheumatoid arthritis is a chronic inflammatory disease which occurs with rapid proliferation of synovial tissue. Prevalence is estimated to be 0.8 percent worldwide, with women twice as likely to develop the disease as men. About 30% of persons untreated with this condition become permanently work-disabled within two to three years of diagnosis [1]. Natural products are commonly used to reduce the inflammatory response in folk medicine. Some

natural products with anti-inflammatory activity including curcumin, lyprinol, bromelain, flavonoids, saponins, marine sponge natural products and *Boswellia serrata* gum resin. Natural products play a significant role in human health in relation to the prevention and treatment of inflammatory conditions [2].

Inflammation is the response of tissue to any form of injury. It is a part of the body's defense mechanism and its purpose is to coun-

*Corresponding Author (s): AS Jacob, Nova Southeastern University, College of Medical Sciences, USA, E-mail: Audrey.jacob@unwimona.edu.jm

teract effects of injurious stimuli, and to begin the process of healing. Inflammation causes an increase in blood flow, infiltration of white blood cells and fluids into the infected area [3]. An inflammatory response can either be acute or chronic. Acute inflammation is a series of events which begins within seconds to minutes following injury of tissues. It is short lived and arises from physical and chemical damage, pathogen invasion, tissue necrosis or an immune response [4]. White blood cells, mainly macrophages and neutrophils are involved and their actions manifest cardinal signs such as: pain (dolor), heat (calor), redness (rubor), swelling (tumor) and sometimes loss of function [5]. Chronic inflammation may last for several days or months. It has a delayed onset and mainly arises due to persistent infection, presence of foreign bodies or autoimmunity, prolonged exposure to toxic agents. It involves mainly macrophages, lymphocytes eg. T cells, B cells and also fibroblasts. The signs of inflammation are not as clearly defined as with acute inflammation, however chronic inflammation allows for specificity as immunity is acquired [6].

In rheumatoid arthritis autoimmunity is selective to attack the joints. Based on 2010-2012 data from the National Health Interview Survey there is an estimate of about 52.5 million (22.7%) adults ≥ 18 years diagnosed with arthritis.

This is a preliminary study done to investigate the effectiveness of a methanolic ackee leaf extract in treating inflammation in the Complete Freund's adjuvant arthritic (CFA) model. Freund's Adjuvant is a water-in-oil emulsion containing heat-killed mycobacteria or mycobacterial cell wall components, which induces chronic inflammation in the rat knee joint due to the presence of the mycobacterium tuberculosis [7]. Adjuvants are used to elicit an immune response in the body of animals since it stimulates characteristic features of inflammation which include swelling, polymorph nuclear infiltration, tissue destruction and pain at the affected site [8]. An essential component of this response is an intense inflammatory reaction at the site of antigen deposition resulting from an influx macrophages lymphocytes, plasma cells and leukocytes which are able to interact with antigens [9]. It process now initiates lymphocyte mediated immune response called delayed-type hypersensitivity or type 4 hypersensitivity. This type of hypersensitivity has no antibodies but involves cells such as CD4+ cell, TH1 and TH2, CD8+ cells eg CTL, macrophages and eosinophils.

The antigen is picked up by antigen presenting cells which presents it on surface of MHC2 (major histocompatibility complexes) molecules [10] Macrophages secrete IL12 and IL18 which causes activation of CD4+ TH1 cells and natural killer cells. TH1 cells in turn releases IL2 which causes self-proliferation and also IL4 or

interferon gamma [11]. They in turn activate the macrophage to cause increase phagocytosis and increase killing of antigen by the increase production of nitric oxide and increase production of oxygen radicals, which can also cause tissue damage.

Plant extracts have been effectively used in folklore practice to treat symptoms of disease conditions; also they are inexpensive and show fewer side effects. *Blighia sapida* (ackee) plant is known to have medicinal properties such as anti-oxidant, anti-inflammatory and anti-diabetic [12].

The ackee is found in abundance in the Guinean forests of West Africa and was brought to Jamaica during the period of the African slave trade in the eighteenth century [13]. The tree consists of a woody bark, thick branches and pretty red and yellow fruit when ripe. Ackee belongs to a plant family called Sapindaceae (soapberry). Studies have shown that almost many parts of this plant contains medicinal properties, the bark is purported to have anti-edema properties useful in reducing intercostal pains. The ash of the dried husk and seeds are used in the preparation of soap and extract from the leaves used as eye drops for conjunctivitis [14]. The saponin content of the ackee leaf extract is an amphipathic oligosaccharide linked to a mono-, di-, or triterpene, which is often used in medicinal products. This plant can also be used as an adjunct to boost the immune system [15].

4. Materials & Method

Ackee leaves were collected from the Mona area in Jamaica. The leaves were authenticated by the department of Botany- Herbarium. Voucher specimen was deposited under the number #36010.

Drugs and Equipment: Saline 0.2 ml, Ackee leaf extract, Diclofenac, Pentobarbital, Urethane, Tape Measure, and 29 Gauge needles. Rotary evaporator (Buchi Ins, DE, USA).

5. Preparation of Extract

Leaves were washed in 1% detergent, dried and ground to a powder and placed in a separating funnel. Extraction done with a volume of 1000ml methanol as the partitioning agent. The extract was concentrated using a rotary evaporator.

6. Ethics Approval

Ethics approval was received from the ethics committee of the University of the West Indies Ethics Committee. Faculty of Medical Sciences.

7. Animals

24 male Sprague-Dawley rats (weighing 150g-320g), were used in this study. Animals were kept in cages with free access to water

and a standard diet under a 12:12 hour dark-light cycle. All animals were sacrificed (10% urethane) at the end of experiments and specimens of knee joint and blood were collected for histopathological examination and hematology analysis. Fixation was done in neutral buffered formalin using 5 μ thick paraffin sections using hematoxylin and eosin [16].

8. Chemical

Diclofenac was used as the positive control (Merck, Germany). Complete Freund's adjuvant (CFA) was purchased from Sigma Chemical Co. (St Louis, MO, USA). All other chemicals, unless otherwise specified, were from Industrial and Technical supplies Ltd. (ITL) Jamaica, W.I.

9. Pharmacological studies

9.1. Induction of chronic inflammation

24 rats were placed into (n=6/gp). The left knees of rats in groups 1-4 were shaved and anesthetized with pentobarbital sodium, 10mg/ml to facilitate the injection of 0.5 ml CFA into the synovial cavity of the left knee of each rat except those in group 4.

Rats from Group 1 were given Diclofenac 25mg/ml, group 2 rats were given 120mg/ml of ackee leaf extract and rats from group 3 were given 0.2ml of saline via oral gavage. All administrations were via oral gavage 30 minutes before the injection of 0.5ml of CFA (containing 1mg/mL of heat-killed mycobacterium) into the synovial cavity of the left knee. Rats from each group received the same course of extract treatment daily for a period of 28 days, except rats in group 4. After experiment was complete all animals were sacrificed with 10% urethane (Sigma Aldrich, UK). Blood was taken in heparin tubes for hematology studies and joints for histology assessment.

10. Measurement of Knee Swelling

Throughout the 28 days and one day before the experiment the left knee of each rat was measured using tape measure [17]. The measurement was done daily in triplicate to reduce errors and averaged. The initial measurements of the knees (Day 0) of the rats were recorded 30 minutes after the injection of CFA to discount volume changes that may have occurred due to CFA injection. Daily changes seen in the size of the rat knees were recorded and used to compare the swelling seen between control rats and the two test groups.

At the end of the investigation the percentage change in the size of the knee joints and the percentage inhibition were calculated.

Formula to calculate percentage change in knee joint =

$$\frac{(\text{Day 1}-\text{Day 0}) \times 100}{\text{Day 0}}$$

Formula for calculating the percentage inhibition caused by the test groups.

$$\frac{(\text{Control}-\text{Test group}) \times 100}{\text{Day 0}}$$

10. 1. Data Analysis

Data is represented as mean \pm SEM as measurements, the Anova test used.

11. Acute Toxicity

This procedure was done according to the Organization for Economic Co-operation and Development (OECD) Guidelines for Testing Chemicals; Acute Oral Toxicity- Fixed dose procedure 2001.

Twelve mice (22g to 25 g) were fasted before given the ackee leaf extract orally. Three mice per group (total 12 mice) were assigned. Group 1 (n=3) served as the control group (saline), a second group (n=3) was given 300mg/kg of the extract, a third group (n=3) was given 1000 mg/kg of the extract and the fourth group (n=3) was administered 2000 mg/kg of the extract all animals were observed for a period of 72hrs to note if toxicity occurred. Animals which survived were returned to the animal house for care.

12. Results

Effects of Ackee leaf extract and diclofenac on CFA-induced arthritic knee joints of rats.

Injection of CFA into the joints of the rats of the saline control group caused maximum swelling in the knee circumference by 62.72%, on the second day. A large reduction in swelling to 40% was documented by day 28 (**Figure.1a**)

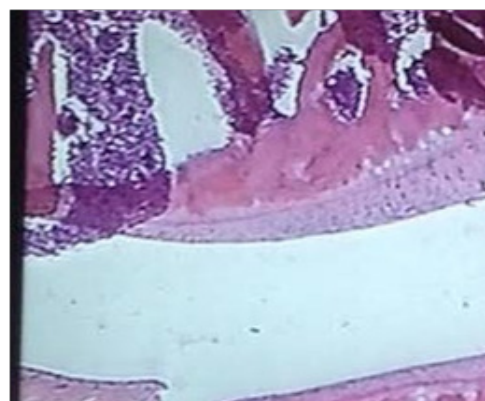


Figure 1: Diclofenac groupx40. Cartilage intact with chondrocytes arranged.

In the extract-treated group, maximum swelling of $48.60\% \pm 0.113$ was recorded at day two, after a period of 28 days the extract cause reduction of swelling in the knee joints in animals by 36.3%. (Fig.1a) In the diclofenac treated group, knee joint swelling was reduced by 74.1 %.($p < 0.05$) The Diclofenac group showed a reduction in swelling to 2% ($p < 0.05$).

On completion of experiments animals were sacrificed using Urethane (10%). Knee joint were collected for fixation and histopathological examination. Fixation process was done using buffered formalin and 5 μ thick paraffin sections, stained with hematoxylin and eosin. Blood samples were also collected for hematology assessment, Total and differential leukocytes counts seen in Control and Ackee extract treated group of animals.

There was a reduction in the total leukocyte count of the blood of the animals which received ackee leaf extract in comparison with those which received saline (Figure 2a).

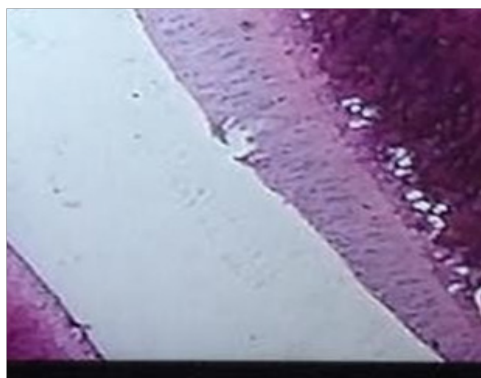


Figure 2: CFA +Extract x 10: New bone formation with mild changes in synovium and some cartilage preservation. Chondrocytes still well aligned.

The total white blood cells fell from a maximum of 14.1×10^3 in the saline group to 5.2×10^3 in the extract group (decrease by 63%). Differential blood counts also revealed total lymphocytes counts in the extract groups were smaller (3.8×10^3) than those in the saline group (10.2×10^3). Monocytes and precursors (MID) and GRAN (Neutrophils, eosinophils and basophils) were also seen to be at smaller levels. MID count was seen at 0.5×10^3 and GRAN was seen at 0.9×10^3 in the extract groups, while those of the saline group were 1×10^3 (MID) and 2.4×10^3 (GRAN) respectively ($p < 0.05$). The levels however were insignificant for the diclofenac group ($p \text{ value} \geq 0.05$).

13. Acute Toxicity Results

No deaths reported in mice population. There was no physical change in gait and animals appeared well oriented to time and space and very alert to stimuli of excess light and loud noise. At all dose levels, including the maximum dose of 2000mg/kg, the ackee leaf extract appears to be non-toxic. Also observation within

72h post administrations of extracts all mice were alive and well-oriented.

Images produced from the knee joints of the animals showed that the ackee leaf extract caused some degree of cartilage preservation (Fig 2.). Diclofenac seems to have offered protection against cartilage degradation (Fig.1).While CFA treated knee joint showed severe cartilage damage (Figure 3) compared to control joints with saline alone which was still intact without inflammatory signs.(Figure 4).

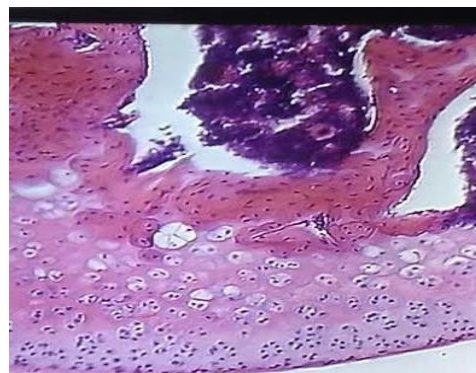


Figure 3: Arthritic Joint (CFA-induced) x 40: Degenerative changes in cartilage, erosion of bone. Synovial space not well-defined (red arrow) chondrocytes rearrangement.

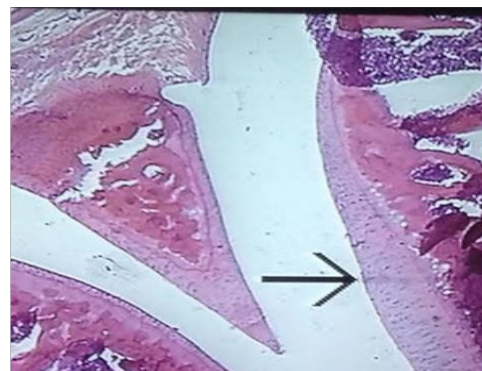

Figure 4: Saline control x20. Without CFA. Well defined synovial space. Good arrangement of Chondrocytes.

14. Discussion

Medicinal plants have been used in folklore practice for the treatment of pain and inflammation. The scientific community is actively searching for new bioactive agents from herbal extracts to treat diseases associated with pain and inflammation. In this study, experimental model of Arthritis was induced with Complete Freund's Adjuvant (CFA) in the knee joints of the rats.

Adjuvant-induced arthritis involves a single injection of CFA into the joint which results in lymphatic drainage and arthritis symptoms in the joints [18].Figure.4, shows saline control, non-arthritic joint with bone and cartilage intact while Fig 3 shows increase distortion of the knee joints along with tissue residue in

synovial space as a result of the effect of Freund's Adjuvant administration.

. Rats treated with saline alone showed no swelling (Figure.4). Inhibition with diclofenac (Figure.1) causes the greatest amount of reduction in swelling and preservation of knee joint. Percentage inhibition with diclofenac was calculated to be 74.1%. Diclofenac is a known non-steroidal anti-inflammatory drug. It acts by inhibiting cyclooxygenase (COX) enzyme to cause a blockade of prostaglandin synthesis. In comparison to the saline control group, diclofenac produced significant reduction in the size of the knee joints ($p < 0.001$).

Phytochemical evaluations of the ackee leaf suggest that this anti-inflammatory action is due to the presence of an active compound known as saponin. Saponins are able to block the cyclooxygenase enzyme and thus subsequently prostaglandin synthesis [19]. This could account for the reduction produced in the knee joints of the animals. Additionally saponins inhibit histamine and serotonin synthesis, which may further inhibit swelling in the joints [20].

In comparing the extract group with the diclofenac group, diclofenac showed significant inhibition and thus resulted in smaller swellings in the joints ($P \leq 0.001$). The possible deduction is that diclofenac was more efficacious in inhibiting swelling in the knee joints and that the actions of saponins may be less efficacious than diclofenac.

There was a reduction in white blood cell counts in the diclofenac group ($p < 0.0001$) when compared to ackee extract test group ($p < 0.05$). This indicates that diclofenac was more effective in reducing Leukocyte count. During an inflammatory response there is an increase in the infiltration of white blood cells and fluids rushing into infected area [21]. These white blood cells are responsible for the defensive and destructive mechanism from the invading pathogens, however to do so they release many chemical substances to destroy these pathogens which can result in the destruction to the cartilage (Figure.2) and blockade of signaling of inflammatory responses. It is important to consider that white blood cell count gives an account of the severity of infection in inflammatory conditions. In arthritic conditions there is a mild to moderate rise in the WBC count. In this study complete [22]. Freund's adjuvant causes cyclooxygenase products, prostaglandins and free radical invasion to precipitate rat adjuvant arthritis. Images from histochemical preparations of the knee joints of the animals revealed that the ackee leaf extract caused some amount of cartilage preservation (Figure 2) when compared to that of (Figure 3), which received only the CFA. The normal cells of the cartilage (chondrocytes) are uniformly arranged, glassy, and

evenly dispersed in Figure 2, 1 and 4. The morphological details of the cartilage of the rats which received the extract revealed that most of the chondrocytes were still evenly distributed and arranged in order. Diclofenac group showed very little changes in the arrangement of the cells. Comparison of the histology assessment of knee joint in the arthritic

(Figure 3) and extract-treated (Figure 2) animals indicate that the extract of ackee leaves possess anti-arthritic effect.

In acute toxicity experiments Ackee leaf extract appears to be non-toxic at a dose of 2000 mg/kg. There was no change in gait, no observed state of disorientation nor somnolence. No deaths were documented and signs of toxicity were not observed in rat treated with extracts at dose 2000 mg/kg. This extract can be deemed safe for use in folklore practice in Jamaica, since some degree of safety has been established. However this study lacks valuable information relating to effects of ackee leaf extract in chronic toxicity studies. Future work should be done to identify the pure bioactive compound which is producing anti-inflammatory effects and further toxicity evaluations can be done with the pure component.

Numerous side effects are associated with drugs that are used to treat Rheumatoid arthritis. (NSAIDs) are used in the treatment of inflammation. NSAIDs are not the best drugs for individuals who present with adverse drug reactions (ADRs), while on NSAIDs therapy these includes, stomach ulcers, liver damage [22]. In acute toxicity experiment, it appears that ackee leaf extract contains secondary metabolites which provide a safe alternative for the treatment of inflammation in the absence of expensive pharmaceutical agents such as NSAIDs.

15. Conclusion

It can be concluded that the ackee leaf extract can be useful in reducing the swelling of the knee joints, it does not increase white blood cell count and additionally gives some protection to cartilage integrity. The extract should therefore be further purified and examined in greater details to better assess its anti-inflammatory properties.

16. Acknowledgements

The authors wish to thank the technical staff of the Sections of Pharmacology and Anatomy of The University of the West Indies, Kingston Jamaica. Funding granted by the Pharmacology Section, University of the West Indies, Mona.

References

1. Rindfleisch JA, Muller D. Diagnosis and management of rheumatoid arthritis. *Am Fam Physician* 2005;72:1037-47.
2. Yuan G1, Wahlqvist ML, He G, Yang M, Li D. Natural products and anti-inflammatory activity Asia Pac. *J Clin Nutr.* 2006;15 (2):143-52.
3. Newbould, BB. Chemotherapy of arthritis induced in rats by mycobacterial adjuvant. *Br J Pharmacol Chemother.* 1963;21:127-36.
4. Rahman S, Gudetta B, Fink J, Granath A, Ashenafi S, Aseffa A, et al. Compartmentalization of immune responses in human tuberculosis: few CD8+ effector T cells but elevated levels of FoxP3+ regulatory T cells in the granulomatous lesions. *Am J Pathol.* 2009;174:2211-2224.
5. Bhatia D, Bejarano T, Novo M. Current interventions in the management of knee osteoarthritis. *J Pharm Bioall Sci.* 2013;5:30-8.
6. Coico R, Sunshine G. Elements of innate and adaptive immunity. In *Immunology: A short course* (6th ed., pp. 11-14). Hoboken, N.J. Wiley-Liss. 2009.
7. White RG. Role of adjuvants in the production of delayed hypersensitivity. *Br. Med Bull.* 1967;23:39-44.
8. Hardy MM, Seibert K, Manning PT, Currie MG, Woerner BM, Edwards D, Koki et al. Cyclooxygenase 2-dependent prostaglandin E2 modulates cartilage proteoglycan degradation in human osteoarthritis explants. *Arthritis Rheum.* 2002;46:1789-1803.
9. Billiau A, Matthys P. Modes of action of Freund's adjuvants in experimental models of autoimmune diseases. *J Leukoc Biol.* 2001;70(6):849-60.
10. Mahdavian Delavary B, van der Veer WM, van Egmond M, Niessen FB, Beelen RH. Macrophages in skin injury and repair. *Immunobiology.* 2011;216(7):753-62.
11. Kobayashi K, Kaneda K. Immuno-pathogenesis of delayed-type hypersensitivity. *Microscopy research and Technique.* 2001;53(4):pp.241-245.
12. Díaz M and Rossini C. Bioactive Natural Products from Sapindaceae Deterrent and Toxic Metabolites Against Insects. *INTECH Journals.* 2012;287-290.
13. Ekue M, Sinsin B. Uses, traditional management, perception of variation and preferences in ackee (*Blighiasapida K.D. Koenig*) fruit traits in Benin: implications for domestication and conservation. *J Eth Eth.* 2010;6(12).
14. Dewole O, Popoola O. Chemical, Phytochemical and antibacterial screening of extracts of *B. Sapida* for agricultural and medicinal relevance. *Nature and Science.* 2013;11.
15. Mazzola E, Ainsley P, Kennelly E. Utility of coupled-HSQC experiments in the intact structural elucidation of three complex saponins from *Blighiasapida*. *Carbohydr Res.* 2011;346(6):759-68.
16. Bancroft J D, Gamble M. *Theory and Practice of Histological Techniques.* 6th ed. Oxford: Churchill Livingstone Elsevier. 2008;123-126.
17. Levy, A S, Simon O R, Shelly, J, Gardner M. 6-shogaolreduced-chronic inflammatory response in knees of rats treated with complete Freund's adjuvant. *BMC Pharmacol.* 2006;6:12.
18. Aldrich M B, Sevick-Muraca E M. Cytokines are systemic effectors of lymphatic function in acute inflammation. *Cytokine.* 2013;64:362-369.
19. Kawai M, Modder UI, Khosla S, Rosen CJ. Emerging therapeutic opportunities for skeletal restoration. *Nat Rev Drug Discov.* 2011;10:141-156.
20. Moura AC1, Silva EL, Fraga MC, Wanderley AG, Afiatpour P, Maia MB. Antiinflammatory and chronic toxicity study of the leaves of *Ageratum conyzoides L.* in rat. *sPhytomedicine.* 2005;12(1-2):138-142.
21. Sharma B, Kumar P. Extraction and pharmacological evaluation of some extracts of *Tridax procumbens* and *Capparis deciduas*. *Int J Appl Res Nat Prod.* 2009;1:5-12.
22. Legein B, Temmerman L, Biessen EA, Lutgens E. Inflammation and immune system interactions in atherosclerosis. *Cell Mol Life Sci.* 2013;70 (20):3847-3869.
23. Hegen, M, Keith JC, Collins, Nickerson-Nutter CL. Utility of animal models for identification of potential therapeutics for rheumatoid arthritis *Annu. Rheumatic Dis.* 2008; 67:1505-1515.