

3D Power Doppler Ultrasound of Subendometrial Area and its Relation to Endometrial Pathology in Women with Postmenopausal Bleeding

Ehab H M Hasanein, Mohamed Elsokkary*, Abd Elmonsef A Sedek, Farid Ahmed Elsayed Kasab and Muhammed I M Soliman

Department Obstetrics and Gynecology, Faculty of Medicine, Al-Azhar University, Egypt

*Corresponding Author (s): Mohamed Elsokkary, Department Obstetrics and Gynecology, Faculty of Medicine, Al-Azhar University, Egypt, Email: mohammedelsokkary1@yahoo.com

Volume 1 Issue 1 - 2018

Received Date: 24 May 2018

Accepted Date: 7 June 2018

Published Date: 9 June 2018

1. Abstract

1.1. Background: Postmenopausal bleeding is a common symptom in general gynecological practice. Various benign genital causes of postmenopausal vaginal bleeding include atrophic vaginitis, endometrial poly, cervical polyps, endometrial hyperplasia and submucosal fibroids. Endometrial cancer is the most common form of gynecological cancer in developed countries, and it is the fourth most common malignant tumor among women worldwide. Abnormal uterine bleeding is usually the first symptom; therefore, appropriate evaluation of women with premenopausal or postmenopausal bleeding will allow for early diagnosis of endometrial carcinoma and the best opportunity for cure. Endometrial cancer occurs in both the pre-menopausal and postmenopausal periods peaking when patients are in their 50s and postmenopausal uterine bleeding is the most common symptom of endometrial cancer. Endometrial sampling and histopathologic can provide a provisional diagnosis. The recent developments with ultrasound equipment enable new imaging techniques for volume scanning.

1.2. Objectives: This study aims to assess the accuracy of endometrial volume and vascularization index assessed by three-dimensional ultrasound in prediction of endometrial carcinoma in woman with postmenopausal bleeding in comparison with histopathology.

1.3. Patients and methods: This prospective study was conducted on 100 women with postmenopausal bleeding having endometrial thickness ≥ 5 mm. During study period, they were evaluated as regard BMI,

ultrasonographic assessment of endometrial thickness, and pathological findings.

1.4. Results: Patient means age was 59.3 years (range, 45-75 years). Mean age at menopause was 51.2 (range, 45-55 years). Mean years since menopause was 7.8 (range, 2-20 years). Mean body mass index (BMI) was 33.6 kg/m² (range, 25.3-48.9 kg/m²). Histological diagnoses were endometrial cancer (31 cases; 31%), endometrial hyperplasia (26 cases; 26%), endometrial polyp (23 cases; 23%) and atrophy

(20 cases; 20%). Division according to endometrial pathology into 4 groups was done. Group included 31 patients with malignant endometrium. Another group was 20 patients with atrophic endometrium. Another one included 26 patients with endometrial hyperplasia. The last group included 23 patients with endometrial polyps. There were high significant different relations between endometrial thickness and volume and histopathological diagnosis and between VI and VFI and histopathological diagnosis and a significant relation between FI and histopathological diagnosis.

1.5. Conclusion: 3D endometrial volume and 3D power doppler flow indices improves the prediction of endometrial carcinoma in women with postmenopausal bleeding.

2. Keywords: Postmenopausal bleeding; Endometrial pathology; Three dimensional doppler ultrasound

3. Introduction

Postmenopausal bleeding is a common symptom in general gynecological practice. The incidence of vaginal bleeding in postmenopausal women is approximately 10% immediately after menopause and 5% of all cases of menopause [1,2]. Various benign genital causes of postmenopausal vaginal bleeding including atrophic vaginitis, endometrial polyp, cervical polyps, endometrial hyperplasia and submucosal fibroids. However, 10% of all women presenting with postmenopausal bleeding may have endometrial malignancy. Clinical investigations for those patients are mainly directed to exclude malignant and premalignant lesions [3,4]. Endometrial cancer is the most common form of gynecological cancer in developed countries, and it is the fourth most common malignant tumor among women worldwide [5]. Abnormal uterine bleeding is usually the first symptoms, therefore: appropriate evaluation of women with premenopausal or postmenopausal bleeding will allow for early diagnosis of endometrial carcinoma and the best opportunity for cure [6]. Endometrial cancer occurs in both the pre-menopausal and

postmenopausal periods peaking when patients are in their 50s and postmenopausal uterine bleeding is the most common symptom of endometrial cancer [3]. To our knowledge, endometrial sampling and histopathologic review can provide a provisional diagnosis [7]. Transvaginal ultrasound as non-invasive scan is the most commonly used first line investigation for women with postmenopausal endometrial bleeding before endometrial sampling. Usually a thick endometrium is indicative of further invasive evaluation such as endometrial sampling and/or hysteroscopy [8,9]. However, conventional two-dimensional (2D) ultrasound cannot assess all possible endometrial pathologies. The recent developments with ultrasound equipment enable new imaging techniques for volume scanning. Unlike 2D ultrasound, three-dimensional (3D) ultrasound visualizes the whole endometrium on a coronal plane and can integrate Doppler imaging to display the vascularity in the interested areas. In this study, we will evaluate the role of three-dimensional power Doppler ultrasonography in detection of lesions in women with postmenopausal bleeding and evaluate the efficacy of 3D PD-US to differentiate between benign endometrial lesion and endometrial carcinoma in women with postmenopausal bleeding.

4. Patients and Methods

This prospective observational study was carried out in the Obstetrics and Gynecology Department of Sayed Galal University Hospitals. One hundred patients with postmenopausal bleeding are recruited from attendees of the Outpatient Gynecological Clinic and Inpatient Gynecological Ward at Sayed Galal University Hospital.

5. Inclusion Criteria

- Menopausal woman with natural menopause which defined as absence of menstruation for at least one year in women older than 45 years provided that the amenorrhea was not explained by medication or disease.
- Patients complaining of postmenopausal

bleeding.

- Double-layer endometrial thickness more than 5 mm by baseline transvaginal sonography.
- Definitive endometrial histologic diagnosis was obtained at our center.

6. Exclusion Criteria

- Endometrial thickness < 5 mm.
- Patients with bleeding tendency that originated from the cervix, vaginal or vulva.
- Patients who had systemic and hematological disorders.
- Patients with uterine bleeding due to disorders in the pelvis other than the uterus.
- Patients with uterine bleeding due to use of oral anticoagulant drugs as warfarin or heparin, tamoxifen citrate or any kind of hormonal replacement therapy.
- Patients with previous definitive endometrial histological diagnosis that was not obtained at our center.

7. Methods

Ethical approval for further evaluation and use of data were granted by the Research Ethics Committee. Data were collected in pre-organized data sheet by the researcher. The details of the procedure, aim of the work, benefit and risk of the trial had been explained to all patients. All participants signed an informed consent (written consent) after explaining benefits and risks of the trial and have the right to leave the study at any time. All patients who included in this study are subjected to complete medical history, general examination, local examination, basic laboratory investigations, transvaginal ultrasound examination and endometrial sampling. The primary outcome measure is the value of endometrial volume, VI, FI, or VFI as assessed using 3-D power Doppler for prediction of endometrial lesions in women presenting with postmenopausal bleeding.

8. Results

A high significant difference ($p < 0.001$) is found between atrophic versus hyperplasia, atrophic versus endometrial polyp and atrophic versus carcinoma (**Table 1**).

Table 1: Relation between endometrial thickness and histopathological diagnosis

	Endometrial thickness (mm)	F ratio	P value
	Mean ± SD		
Atrophic	5.9 ± 0.8	13.5	< 0.001 (HS)
Hyperplasia	7.4 ± 1.7		
Endometrial polyp	8.9 ± 2.2		
Carcinoma	11.3 ± 3.8		

A high significant difference ($p < 0.001$) is found between atrophic versus carcinoma and hyperplasia versus carcinoma (**Table 2**).

Table 2: Relation between endometrial volume and histopathological diagnosis

	Endometrial volume (cm ³)	F ratio	p value
	Mean ± SD		
Atrophic	2.5 ± 1.3	8.5	< 0.001 (HS)
Hyperplasia	3 ± 1.6		
Endometrial polyp	3.5 ± 2.2		
Carcinoma	5 ± 3.7		

A high significant difference ($p < 0.001$) is found between atrophic versus hyperplasia, atrophic versus endometrial polyp and atrophic versus carcinoma (**Table 3**).

Table 3: Relation between VI and histopathological diagnosis

	VI Mean ± SD	F ratio	p value
Atrophic	0.5 ± 0.4	6.9	< 0.001 (HS)
Hyperplasia	1.3 ± 0.5		
Endometrial polyp	1.3 ± 0.6		
Carcinoma	1.9 ± 1.5		

A significant difference ($p < 0.05$) is found between atrophic versus endometrial polyp (**Table 4**).

Table 4: Relation between FI and histopathological diagnosis

	FI Mean \pm SD	F ratio	p value
Atrophic	19.2 \pm 13	4.6	0.005 (S)
Hyperplasia	26.5 \pm 9.5		
Endometrial polyp	29 \pm 5.3		
Carcinoma	27.8 \pm 5.5		

A high significant difference is found between atrophic versus endometrial polyp and atrophic versus carcinoma (**Table 5**).

Table 5: Relation between VFI and histopathological diagnosis

	VFI Mean \pm SD	F ratio	p value
Atrophic	0.1 \pm 0.05	6.2	< 0.001 (HS)
Hyperplasia	0.1 \pm 0.1		
Endometrial polyp	0.3 \pm 0.1		
Carcinoma	0.4 \pm 0.8		

9. Discussion

Malignancy is more common with postmenopausal bleeding than perimenopausal; still the most common cause of postmenopausal bleeding is atrophic vaginitis or endometritis. Bleeding after menopause is a widespread problem, with 10% - 15% of cases later suffering from cancer of the endometrium. It differs from other malignancies, in that early symptomization is common, allowing early cure. Survival drops with late stages and so studies should strive to increase the precision of various diagnostic practices. Postmenopausal bleeding is an early clinical sign of endometrial malignancy. The finding of a thin (< 5mm) endometrium at transvaginal ultrasound examination in women with postmenopausal bleeding, rules out about 99% of endometrial cancers [10]. There is persistent debate regarding the most appropriate methods for investigating and managing PMB. Transvaginal sonography currently is considered to be the first-step technique to be performed in women with postmenopausal bleeding because it may reliably rule out endometrial cancer when endometrial thickness is less than 5 mm and because it is cost-effective. However, a thickened endometrium is a non-specific finding, and additional tests are warranted. Most current protocols include the

use of endometrial office biopsy. histopathological diagnosis which is the gold standard for diagnosis but what is against with is that is expensive and need more preparation and may be done outpatient or inpatient like D&C procedure itself, although highly diagnostic, yet it has many limitations, including the need for general anesthesia, being a blind procedure with possible complications [11]. Yaman et al [12] have claimed that endometrial volume measurements taken using 3D ultrasound imaging discriminate better between benign and malignant endometrium than do endometrial thickness measurements. There is no method to distinguish women with transient endometrial adenomatous hyperplasia from women with neoplastic potential. Whenever adenomatous hyperplasia of the endometrium appears, appropriate treatment or long-term surveillance is mandatory [13]. So, we considered malignant or premalignant finding at the same group. Three-dimensional (3D) ultrasound represents a technical development which has led to an improvement in the quality and precision of ultrasound examination. With a vaginal probe, structures can be represented in three planes and the scanned volume can be layered into countless cross-sections. Before examining the clinical role of a new method, its reproducibility has to be checked. To date, no study has assessed the reproducibility of 3D endometrial volume measurement in patients with PMB. This study aims to assess the accuracy of endometrial volume and vascularization index assessed by three-dimensional ultrasound in prediction of endometrial carcinoma in woman with postmenopausal bleeding in comparison with histopathology. This prospective study was conducted on 100 women with postmenopausal bleeding having endometrial thickness \geq 5 mm. During study period, they were evaluated as regard BMI, ultrasonographic assessment of endometrial thickness, and pathological findings. Patient mean age was 59.3 years (range, 45-75 years). Mean age at menopause was 51.2 (range, 45-55 years). Mean years since menopause was 7.8 (range, 2-20 years). Mean body mass index (BMI) was 33.6 kg/m² (range, 25.3 - 48.9 kg/m²).

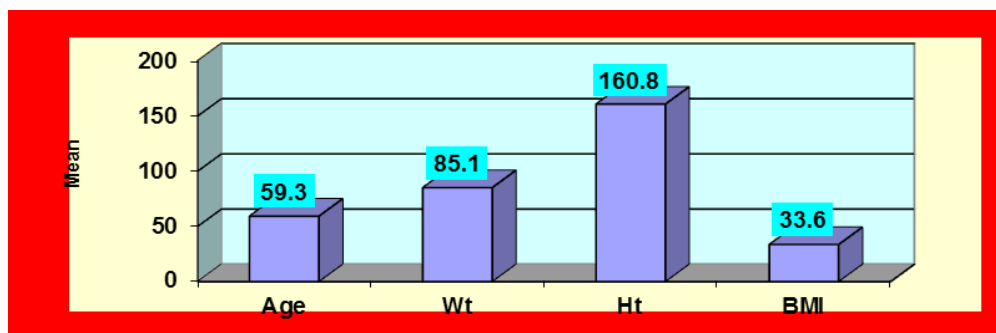


Figure 1: Personal characteristics




Figure 2: Histopathological diagnosis

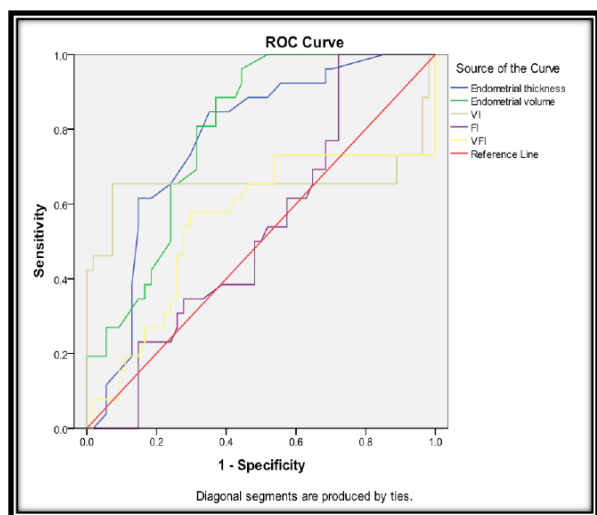
Histopathological diagnoses (Figure 1,2) were endometrial cancer (31 cases; 31%), endometrial hyperplasia (26 cases; 26%), endometrial polyp (23 cases; 23%) and atrophy (20 cases; 20%). Opolskiene et al [14] determined whether endometrial volume or power Doppler indices as measured by three-dimensional (3D) ultrasound imaging can discriminate between benign and malignant endometrium, compared their diagnostic performance with that of endometrial thickness measurement using two-dimensional (2D) ultrasound examination, and determined whether power Doppler indices add any diagnostic information to endometrial thickness or volume. Median age was 65 years, and 24 (39%) patients were on hormone replacement therapy. Patients with malignant endometrium tended to be older (median age, 73 years vs. 63 years), had a higher body mass index (median, 31 kg/m² vs. 27 kg/m²) and thicker endometrium (median, 16.2 mm vs. 9.6 mm) than those with benign endometrium, and fewer used hormone replacement therapy (23% vs. 43%). Division according to endometrial pathology into 4 groups was done. Group included 31 patients with malignant endometrium. Another group was 20 patients with atrophic endometrium. Another one included 26 patients with endometrial hyperplasia. The last group included 23 patients with endometrial

polyps. The study included only women with thickened endometrium because women with a thin endometrium have a low risk of endometrial cancer and can be treated expectantly because they do not need additional testing if no other risk factors for endometrial cancer exist. Because of this selection, the prevalence of endometrial cancer is high and therefore does not represent the general population. The study also did not include patients who received tamoxifen or hormone replacement therapy, because it is well-known that these treatments increase endometrial vascularization and may be a potential source of bias. As regarding endometrial volume measurement, in the study by Odeh et al [15], endometrial volume was superior to the flow indices for discrimination between hyperplasia/malignant endometrium and benign endometrium other than hyperplasia, whereas in the investigations by Alcazar and Galvan [16], the flow indices were superior to endometrial volume for discrimination between endometrial carcinoma and endometrial hyperplasia, and between benign and malignant endometrium, respectively. Our study agreed with a study done by Yaman et al [12] which studied 213 cases of postmenopausal bleeding. They found that 42 cases (19.7%) were cancer, 109 cases (51.17%) were benign lesions (polyp-hyperplasia), 62 cases (29.1%) were atrophic authenticated that

both endometrial volume and thickness measurements by 3D and 2D scanning, respectively, were adequately reproducible but that the reproducibility of 3D was superior. Opolskiene et al [14] found that the AUC of endometrial thickness was 0.82, while that of endometrial volume was 0.78. Of the 62 women included in Study 49 (79%) had benign endometrium and 13 (21%) had malignant endometrium. The endometrial volume was larger and the flow indices were higher in both the endometrium and in the subendometrium in patients with malignant endometrium than in those with benign endometrium, but there was substantial overlap between the two categories. The best variables for discriminating between benign and malignant endometrium were endometrial thickness, and endometrial VI and VFI, all having AUC of 0.82. The best logistic regression model for predicting malignancy was that including the variables endometrial thickness and VI in the subendometrium with AUC of 0.86. Using the mathematically optimal risk cut-off value (0.22), the model correctly classified seven more benign cases, but two fewer malignant cases, than the best endometrial thickness cut-off (11.8 mm). Models including endometrial volume and flow indices performed less well than endometrial thickness alone (AUC 0.79 vs. 0.82). Intra-observer reliability was very high for all ultrasound variables. Kim et al [17] applied 3D power Doppler ultrasound (3D PDUS) in women with postmenopausal endometrial bleeding and calculated various ultrasonographic vascular markers. They concluded that endometrial volume measurement may play an important role in discriminating endometrial cancer from benign diseases. The positive cut off value was offered for the prediction of malignancy with an endometrial thickness of 4.05 but the difference in this study that the women with a thin endometrium (<5 mm) were not excluded. The positive cut off value was offered for the prediction of malignancy with an endometrial thickness of 9.5 mm, not as the passive endometrial thickness of 5 mm. This means that endometrial thickness of >5 mm requires further evaluation with methods such as endometrial biopsy, catheter sampling, whole curet-

tage, or hysteroscopic biopsy. However, an endometrium thicker than 9.5 mm is worthy of attention and is evaluated with malignancy in mind. With regard to endometrial volume, a larger volume must be associated with a thick endometrium and, of course, can be related to endometrial cancer. It assessed the cutoff values of endometrial volume for the prediction of cancer as 4.05 mL, which is not small compared with that of the reproductive endometrium. El-Mekki et al [18] reached the following result in Sixty women with postmenopausal bleeding were finally analyzed; 32 (53.3%) women had benign endometrial lesions and 28 (46.7%) had endometrial malignancy. Women tended to have significantly thicker endometrium (11.11 ± 3.61 vs. 5.78 ± 0.94 mm), larger endometrial volume (4.89 ± 3.53 vs. 2.22 ± 1.6), and higher 3DPD flow indices than those with benign endometrial lesions. There was a statistically significant difference between 3DPD and 3D multislice view, with increased vasculature in different planes in malignant cases than in benign cases. The best logistic regression models for predicting malignancy [i.e. the models with the largest area under the curve (AUC)] included endometrial thickness and VFI (AUC 0.984 and 0.884). Even though histopathological examination of the endometrium is the gold standard for the final diagnosis or exclusion of endometrial malignancy, endometrial volume, 3DPD indices, and 3D multislice view are good diagnostic tools in predicting endometrial malignancy in women with postmenopausal bleeding. Regarding the assessment of endometrial vascularization by 3D-PDA, different studies have attempted to identify the diagnostic accuracy of 3D ultrasound scanning in differentiation between non-cancerous and cancerous endometrial. In this study, the best predictor was VI and shows significant difference between: Atrophic vs. Hyperplasia, Atrophic vs. Endometrial polyp and Atrophic vs. Carcinoma). All cases of endometrial cancer exhibited power Doppler signals. Mean endometrial volume, VI, and VFI were significantly higher in endometrial cancer, compared with all other benign diseases. FI was significantly higher in endometrial cancer, compared with endometrial polyp and hyper-

plasia but not when compared with cystic atrophy and submucous myomas. ROC curves are showed that the best predictor for endometrial cancer was VI, which is significantly higher than all other parameters (**Figure 3**).



Area under the curve:

Figure 3: ROC curve

However, he shows that 3-dimensional VIs is not only higher in endometrial cancer, compared with endometrial hyperplasia, but also compared with other benign lesions (such as endometrial polyps or cystic atrophy). This indicates that endometrial vascularization is increased mainly in cases of adenocarcinoma. Three-dimensional VI is higher in endometrial cancer there is difference about the best predictor for endometrial carcinoma. Alcazar et al [19] stated that receiver operator characteristic analysis revealed that VI was the best parameter for the prediction of endometrial cancer with an AUC of 0.90, which is significantly higher than all other parameters. Opolskiene et al [14] found that the two best power Doppler variables (VI and VFI in the endometrium) AUC were 0.82 and 0.82 was not better than endometrial thickness. Using the mathematical best cut-off value for endometrial thickness to predict malignancy (11.8 mm), the sensitivity was 85%, the specificity 71%, the LR + 3.0 and the LR - 0.2. Using the mathematical best cut-off value for VI and VFI in the endometrium, the sensitivity was lower than that of endometrial thickness (69% and 69% vs. 85%), the specificity was higher (84% and 82% vs. 71%), and both the LR+ and LR- were higher. The

following variables added information to endometrial thickness when calculating the risk of malignancy: FI in the endometrium, VI in the shell of the endometrium, and VFI in the shell of the endometrium. The best logistic regression models for predicting malignancy (i.e. the models with the largest AUC) contained endometrial thickness and VFI in the endometrial shell (AUC 0.86) or endometrial thickness and VI in the endometrial shell (AUC 0.86). Because the model including VI manifested higher specificity at sensitivities $\geq 85\%$, it is the best logistic regression model for discrimination between benign and malignant endometrium. At a sensitivity of 85%, only the model containing endometrial thickness and VFI in the shell, or endometrial thickness and VI in the shell had a specificity as high as (71%) or similar (69%) to that of endometrial thickness. At sensitivity 85%, the specificity of VI and VFI in the endometrium was 61%. Models containing endometrial volume and flow indices performed less well than models containing endometrial thickness and flow indices. They also performed less well than endometrial thickness alone. Kim et al [17] analyzed the receiver operating characteristic curves of endometrial For VI, FI, and VFI to assess their predictive value for malignancy the area under the curve was statistically significant in all parameters for the prediction of endometrial cancer VI, FI, and VFI have predictive power for malignancy before the performance of invasive endometrial biopsy. The best predictive cutoff value of the vascular parameters was relative values, but, in this mode setting, the cutoff values were 13.07 for VI, 12.61 for FI, and 3.76 for VFI. Our study found also that the predictive property or ultrasonography characteristics for endometrial hyperplasia the area under the curve for endometrial volume was not significant but reflected endometrial hyperplasia. Endometrial VI and VFI were also not significant; there was no significant difference between other benign and hyperplastic endometrium. The variable findings in the published studies, together with the differences in findings between our study and the others, can confidently be explained by marked variations in study populations and design. Although all publications

cited included only women with abnormal uterine bleeding, there were variations in menopausal state, rate of endometrial cancer, mix of benign histological findings, use of hormone replacement treatment, and endometrial thickening. Also, there were differences in group comparisons between the studies. In this study the best predictor was VI with an AUC of 0.96 which is significantly higher than all other parameters. Significant difference is between: Atrophic vs. Hyperplasia, Atrophic vs. Endometrial polyp and Atrophic vs. Carcinoma). Opolskiene et al [14] found that the diagnostic performance for discrimination between benign and malignant endometrium of 3D ultrasound imaging was not superior to that of endometrial thickness as measured by 2D ultrasound examination, and 3D power Doppler imaging added little to endometrial thickness or volume.

10. Conclusion

We found that the diagnostic performance of 3D power Doppler flow indices added information to endometrial thickness or volume. So, we can conclude that 3D endometrial volume and 3D power Doppler flow indices improves the prediction of endometrial carcinoma in women with postmenopausal bleeding. Clinicians can benefit in adding 3D USG to their routine gynecological workup as it provides fast and accurate results in a relatively cost-effective setting. Vascularization index may replace endometrial thickness as a predictor for endometrial carcinoma. Endometrial volume, FI and VFI may be used for discrimination between benign and malignant endometrium except in cases of endometrial polyp.

11. References

1. Astrup K, Olivarius Nde F. Frequency of spontaneously occurring postmenopausal bleeding in the general population. *Acta Obstet Gynecol Scand.* 2004;83:203-7.
2. Guruwadayarhalli B, Jones SE, Srinivasan V. Hysteroscopy in the diagnosis of postmenopausal bleeding. *Menopause Int.* 2007;13(3):132-4.
3. Rose PG. Endometrial carcinoma. *N Engl J Med.*

1996;335:640-9.

4. Raouf SA, Gupta P, Papaioannou S, Pradhan P. Endometrial thickness for invasive investigations in women with postmenopausal bleeding. *Climacteric.* 2011;14(1):117-20.
5. Parkin DM, Bray F, Ferlay J, Pisani P. Global cancer statistics, 2002. *CA Cancer J Clin.* 2005;55(2):74-108.
6. Sorosky JJ. Endometrial cancer. *Obstet Gynecol.* 2008; 111(2 Pt 1): 436-47.
7. Burbos N, Musonda P, Giarenis I, Shiner AM, Giannougiannis P, Morris EP, et al. Predicting the risk of endometrial cancer in postmenopausal women presenting with vaginal bleeding: the Norwich DEFAB risk assessment tool. *Br J Cancer.* 2010;102(8):1201-6.
8. Dreisler E, Sorensen SS, Ibsen PH, Lose G. Value of endometrial thickness measurement for diagnosing focal intrauterine pathology in women without abnormal uterine bleeding. *Ultrasound Obstet Gynecol.* 2009;33(3):344-8.
9. Goldstein RB, Bree RL, Benson CB, Benacerraf BR, Bloss JD, Carlos R, et al. Evaluation of the woman with postmenopausal bleeding: society of radiologists in ultrasound-sponsored consensus conference statement. *J Ultrasound Med.* 2001;20(10):1025-36.
10. Makled AK, Elmekki SF, El-Refaie TA, El-Sherbiny MA. Three-dimensional power doppler and endometrial volume as predictors of malignancy in patients with postmenopausal bleeding. *J Obstet Gynaecol Res.* 2013;39:1045-51.
11. Trimble CL, Method M, Leitao M, Lu K, Ioffe O, Hampton M, et al. Management of endometrial precancers. *Obstet Gynecol.* 2012;120(5):1160-75.
12. Yaman C, Habelsberger A, Tews G, Polz W, Ebner T. The role of three-dimensional volume measurement in diagnosing endometrial cancer in patients with postmenopausal bleeding. *Gynecol Oncol.* 2008;110(3):390-5.
13. Kurman RJ, Kaminski PF and Norris HJ. The behavior of endometrial hyperplasia: adipose tissue

distribution in postmenopausal women with adenomatous hyperplasia of the endometrium. *Gynecologic Oncology*. 1999;72:138–42.

14. Opolskiene G, Sladkevicius P, Jokubkiene L, Valentin L. Three-dimensional ultrasound imaging for discrimination between benign and malignant endometrium in women with postmenopausal bleeding and sonographic endometrial thickness of at least 4.5 mm. *Ultrasound Obstet Gynecol*. 2010;35(1):94-102.

15. Odeh M, Vainerovsky I, Grinin V, Kais M, Ophir E, Bornstein J. Three-dimensional endometrial volume and 3-dimensional power Doppler analysis in predicting endometrial carcinoma and hyperplasia. *Gynecol Oncol*. 2007;106(2):348-53.

16. Alcazar JL, Galvan R. Three-dimensional power doppler ultrasound scanning for the prediction of endometrial cancer in women with postmenopausal bleeding and thickened endometrium. *Am J Obstet Gynecol*. 2009;200(1):44.e1-6.

17. Kim A, Lee JY, Chun S, Kim HY. Diagnostic utility of three-dimensional power doppler ultrasound for postmenopausal bleeding. *Taiwanese Journal of Obstetrics and Gynecology*. 2015;54(3):221-6.

18. El-Mekkawi SFA, Bahaa AMA, Akl Sherif AA, Sorour RM. Three- dimensional power doppler ultrasound with a three-dimensional multislice view: is it a new modality in endometrial evaluation in women with postmenopausal bleeding? *Evidence Based Women's Health Journal*. 2015;5(3):143-9.

19. Alcazar JL, Castillo G, Minguez JA, Galan MJ. Endometrial blood flow mapping using transvaginal power Doppler sonography in women with postmenopausal bleeding and thickened endometrium. *Ultrasound Obstet Gynecol*. 2003;21(6):583-8.