

EnteroatmosphericFistula: Etiology, Management Aspects and Prevention

Boukerrouche A

Department of Digestive Surgery, University of Algiers,Hospital of Beni-Messous, Algiers, Algeria

Volume 1 Issue 1 - 2019

Received Date: 27 Dec 2018

Accepted Date: 07 Jan 2019

Published Date: 12 Jan 2019

2. Keywords

Enterocutaneous fistula; Enteroatmospheric fistula; Open abdomen; Effluent control; Wound care; Nutrition; Definitive fistula surgery; Abdominal wall reconstruction

1. Abstract

Enteroatmospheric fistula (EAF) is a feared and challenging complication for both patient and care team. EAF is a subset form of enterocutaneous fistula (ECF) and characterized by the absence of the soft tissue overlying the bowel. The open abdomen (OA) is the leading cause of EAF with high risk of fistula formation during dressing changes. The multidisciplinary approach is the key successful management. The principles EAF treatment is based on the correction of intravascular fluid deficit to reverse catabolic state, control of deep abdominal infection using image guided drainage, control of fistula effluent,protection of the skin and the surrounding granulating tissue by using negative pressure wound therapy (NPWT), and achieving a good nutritional condition by providing PN and enteral nutrition if possible. Thespontaneous closure of EAF is extremely rare and definitive reconstructive surgery is almost required. Prevention is the best way to reduce the risks of EAF to occur. This review article discusses diagnosis, etiology, management aspects and prevention of EAFwith specific attention dedicated to effluent control, wound care, nutrition and definitive fistula surgery and abdominal wall reconstruction.

3. Introduction

An enterocutaneous fistula (ECF) is defined as an abnormal communication between the intra-abdominal GI tract and skin and is traditionally considered as one of the most feared complications in gastrointestinal surgery. The mortality of ECF largely varied from 5% to 20% and this variation was due to the heterogeneity of the published studies [1,2]. The associated morbidity is excessive with prolonged hospital stay particularly intensive care unit stay, increased hospital cost and important psychological impact on the patient health [3].The enteroatmospheric fistula (EAF) is a subset form of ECF with several unique characteristics that merit to be highlighted.Oppositely to many postoperative complications, the diagnosis of EAF is often obvious. The typical predisposing situation is the management of open abdomen for at least several days or months.The bowel is exposed directly to environment and a dressing is made to cover the exposed bowel, keep it moist and avoid visceral trauma[Figure 1].

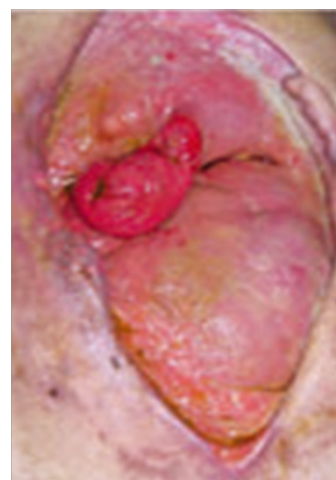


Figure 1: Enteroatmospheric fistula.

The dressing is changed regularly and so a small erosion of exposed and fragilized bowel can occur leading to the fistula formation with drainage of intestinal content into the wound. When occurred, any closure attempt of EAF by performing simple intestinal suture is highly avoided and may result in larger bowel wall opening with aggravating management difficulties.The EAF management scheme is similar to that used in ECF and is based on a few sound tenets including recognition, stabilization, anatomic definition and definitive surgery if

*Corresponding Author (s): Abdelkader Boukerrouche, Department of Digestive Surgery, Hospital of Beni-Messous, University of Algiers, Algiers, Algeria, Tel: +213 661 22 72 98;E-mail:aboukerrouche@yahoo.com

needed [4,5]. However major differences are the difficulty in controlling fistula effluent, skin protection, potential prevention and the complexity of abdominal wall reconstructive surgery. Importantly, a well-organized multidisciplinary approach and evaluation of these patients in specialized center dealing with ECFs are the keys of successful management with improved outcomes. This review article discusses diagnosis, etiology, management aspects and prevention of EAF with specific attention dedicated to effluent control, wound care, nutrition and definitive fistula surgery and abdominal wall reconstruction.

4. Incidence and Classification

The reported overall incidence of EAF varied from 5%–19% [6-9] in damage control laparotomy. This variation in reported incidence was due to the indication for damage control laparotomy (trauma vs non trauma), the number of re-operations for abdominal procedures, and the time to definitive closure. The increase in incidence was linked to the wide use of damage control laparotomy in the surgical community. Depending on location within abdomen cavity, the enteroatmospheric fistulas are two types, deep and superficial. Deep EAFs drain directly into the abdominal cavity and so are more likely a cause of peritonitis. Superficial EAFs are completely extra peritoneal realizing a primarily stoma by draining on the top or the side of the granulating abdominal wound. As the same as ECF, EAF can be classified on the basis of involved segment of GI tract (i.e. Enteroatmospheric, Coloatmospheric gastro atmospheric, etc.) and on the daily output as low-output < 200 ml, high output >500 ml and moderate from 200 to 500 ml.

5. Etiology

EAF develops more commonly following an open abdomen surgery performed for trauma, after damage control and decompressive laparotomies, and in the setting of elective surgery. However, Trauma is largely the leading cause of EAF. EAF also can occur in patients who received surgery for abdominal septic process resulting in the open abdomen secondary to difficulties to achieve abdominal wall closure due to bowel edema or large fascial dehiscence's. The physical characteristics of an open abdomen predispose to the development of EAF. Usually, the bowel is directly exposed to the environment, requiring repeated complicated abdominal dressing changes and so this condition is more likely favorable to EAF development. Despite the utmost care taken to prevent trauma during dressing changes, the multiples manipulations can be traumatic to already edematous and friable bowel resulting in bowel wall erosion and fistula formation. Moreover, the etiologies of postoperative EAF are often related to condition that necessitated surgeries including malignancy, inflammatory intestinal diseases, adhesiolysis, abdominal sepsis,

anastomotic leaks, bowel ischemia and obstruction, and emergency abdominal procedures [10, 11].

6. Prevention

Clearly, prevention is the best way to reduce the risk of EAF. Therefore, take precautions and preventive measures at the first laparotomy is highly recommended to prevent EAF in high risk patient. Before closing the abdominal cavity, the greater omentum should be placed in order to cover the bowel if at all possible, and when non absorbable mesh is used, it should never be in direct contact with bowel. The use of any temporary closure device should protect the underlying bowel and allowing access to the peritoneal cavity. As reported, damage control laparotomies were associated with a high rate of EAF if the abdomen was left open more than 8 days [8,12]. Therefore, every effort should be made to achieve closure of open abdomen as soon as possible to decrease the EAF risk. However, it is difficult for the surgeon to determine the timing of abdomen closure. Typically, the fascia closure should be achieved without leading to intra-abdominal hypertension after the resolution of visceral edema. Several methods have been reported to reduce time to closure including Covering the viscera with a non-adherent drape and achieving skin-only closure when fascial re-approximation is not feasible, however repetitive skin trauma may occur if multiple reoperations are needed prior to definitive closure [12]. The planned ventral hernia (PVH) approach consists of covering the bowel with an absorbable polyglactin mesh fixed to the fascia edges. If enough available, the skin can be closed over drains placed between absorbable material and skin. Therefore, the peritoneal cavity is closed with guaranteed future ventral hernia. This method became less favorable after availability of NPWT, biologic meshes, and other early fascial closure techniques. The use of NPWT systems to achieve closure of an open abdomen has showed a superior results comparing to absorbable mesh [5, 14-16] with statically no significant slightly higher rate of fistula formation (21% vs 5%) [17].

When early closure is impractical after several days, the use of biologic mesh bridges to achieve fascial closure with skin re-approximation over drains or NPWT placed over top of biologic material seems to be an attractive indication. This method achieves the goal of closure over viscera option with lower rate of bowel fistulization [18], however it is associated with a high rate of incisional hernia formation [19,20]. The progressive retraction of the rectus and oblique muscle laterally in open abdomen can plague any effort made to achieve early closure. Therefore, many techniques to prevent abdominal wall retraction have been described and some have been shown to facilitate the achievement of early abdominal wall closure [21-25]. The use of mesh material fixed to the fascial edges associated with progressive tightening at the midline as visceral edema resolves is common in all these

methods. A non-adherent layer or sheet is placed over the viscera inside the peritoneal cavity to prevent adhesions to the anterior abdominal wall that potentially results in frozen abdomen. The NPWT device is applied over the top of the mesh bridge to control fluids and exudate.

The dressing of an open abdomen should be constructed by experienced surgical team members avoiding to place gauze or negative pressure devices directly on the exposed bowel [26]. The presence of an experienced member of the surgical team during the dressing changes of an open abdomen is imperative to ensure avoidance of underlying viscera trauma and to early recognize areas of deserosalization which are likely precursors of an EAF. Finally, the surgical team should always have in mind the greater risk of fistula formation when attempting to achieve a definitive fascial closure of an open abdomen [8,9,27]. As previously stated, nutritional optimization is central in the treatment and prevention of EAF. An open abdomen is a source of extreme catabolic state and increased nutritional requirements. It is well demonstrated that enteral nutrition is more benefit than parenteral nutrition in surgical patients. The early enteral nutrition (less than or equal to 4 days after surgery) has been associated with a significant reduction of EAF rate and time to abdomen closure [28].

7. Management

The management of EAF involves a lengthy and labor-intensive process broken down into phases of treatment so called step-by-step approach [5,26]. This management scheme is similar to that used in case of ECF and is based on diagnosis and stabilization, anatomic definition and fistula reconstructive surgery if needed. Therefore, the management of EAF requires a multidisciplinary team involving surgeons, nursing wound care and nutritionist. The objectives of EAF treatment are control of intestinal effluent, limiting the exposure of surrounding viscera and granulation tissue, eliminating infection, and achieving the best physical condition before definitive reconstructive surgery. However, the major treatment particularities of EAF are the effluent control difficulties and complexity of reconstructive surgery. Once EAF is diagnosed, the control of sepsis and fluid resuscitation constitute the priority because these patients may have already a protein loss with frequently a sepsis from localized wound infection or abdominal deep abscess [26]. The first step in presence of EAF is to eliminate a deep abdominal sepsis and an unrecognized concurrent deep EAF. Abdominal CT scan should be performed as soon as possible after EAF diagnosis to exclude intra-abdominal sepsis, if present, the sepsis should be drained with radiological assistance [29,30]. Importantly, the second step is to define the fistula mapping and evaluate how much contiguous bowel is available for eventual introduction of enteral nutrition [5]. To achieve this goal, some investigations such as fistulography and

oral dye ingestion (as bleu methyl) may be more helpful when used in combination with CT scan [5].

7.1 Effluent control/Skin protection

Controlling the effluent, protecting the exposed bowel, the granulation tissue and the skin surrounding fistula from erosion, inflammation and potential infection should be planned very early to limit consequences. A poorly controlled EAF constitutes a source of embarrassment and discomfort for the patient and frustration for the medical team. Subsequently, it results in the consumption of a tremendous amount of nursing and disposable medical resources. The intestinal content is very corrosive, so early the control of EAF output is critical to limit skin damage that may limit options for subsequent control. First step is to stop oral intake and bowel rest decreases the fistula output significantly. The second step is to use techniques that allow fistula effluent control and protection of the surrounding tissue and skin. Several methods and systems have been developed to achieve effluent control and skin protection [32-35]. Agents such as cellular dermal matrix and fibrin glue have been used to attempt local fistula closure; however, the failure in clinical practice was due to the moisture and continuous intestinal peristalsis [36]. Also performing local extra peritoneal repair of fistula hole followed by split-thickness skin graft to cover the exposed bowel to transform thus EAF to stoma has been described with limited clinical success [37]. Creation of a "floating stoma" which consisted of suturing the perforated wall bowel to a plastic silo piece with hole in it, allowing separation of draining intestine from the peritoneum beneath it [38]. This technique has been reported to be useful in specific circumstances particularly in case of deep EAF [38].

The techniques combining negative-pressure wound management systems with ostomy appliances are more promising with the objective to control fistula effluent, allow granulation of the surrounding tissue, protection of skin and prevention of underlying bowel from trauma [34,39,40]. The original technique initially described by Goverman et al in 2004 [41], consisted of covering the open area and exposed bowel and applying a negative -pressure system to the dressing. So the open abdomen area is covered with a thin layer of impregnated gauze with a hole cut out for fistula opening. In similar fashion, sponges with a hole to accommodate the fistula opening and then a polyurethane drape are placed. Once placed, a hole is cut on the drape and an ostomy appliance or catheter is placed over or within the fistula opening, and then the negative pressure is applied to the entire dressing. Over the years, a few modifications have been added to original technique. As demonstrated by published reports, the negative pressure wound therapy system (NPWT) is very useful to control EAF output and to protect and improve surrounding granu-

lation tissue healing [Figure 2][42,43]. However, the involvement of the stoma therapist or experienced wound care team is highly required [44].The wound care team is more familiar with the akin protection materials such as stoma paste and powder which should be used early. Stoma paste and powder can be used to improve isolation of the fistula. In absence of these care resources, transfer to high level care should be considered. More recently, negative –pressure wound management system has been adapted and used to control the effluent and stop ongoing peritoneal contamination in deep EAF [44,45]. “Floating stoma” method has been used to control deep effluent and limit peritoneal diffusion of infection [38].As reminder, deep EAF with an open abdomen is a surgical emergency in critically illness situation. The goal of surgery is to strictly achieve drainage control of digestive content and to transform such fistula to superficial EAF without attempt to perform any sort of surgical fistula procedure. Therefore, performing fistula surgery in such case can result in increasing intestinal wall defect and aggravating already complicated clinical situation because of bowel edema, mesenteric shortening, and vascularized adhesions [41].There is no specific system designed for the purpose of EAF, however,considerable efforts of the care team are required to design a custom device for patient with EAF and to ensure its effective use on a daily basis. Once the surrounding tissue granulation is achieved, the granulating area is covered by a split-thickness skin graft and thus EAF is managed much likely as a conventional stoma until time of fistula and abdominal wall reconstructive surgery.

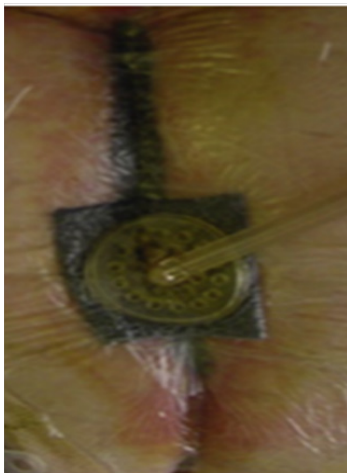


Figure 2: Negative wound pressure system.

7.2 Nutrition

The introduction of early nutrition is key of success in patient with EAF.Nutritional troubles are present in 50% to 90% of patients with an ECF and contribute significantly to the overall morbidity and mortality [46, 47]. Therefore, adequate nutrition is essential for these patients to achieve an acceptable nutritional condition.The goal of nutrition support in patients with EAF is to prevent malnutrition while controlling fistula effluent and not to promote fistula closure [35].Therefore, immediately upon diag-

nosis, correction of fluid and electrolyte imbalances are required to normalize acid base balance and quit the inflammatory process. The fluid needs can be very high in the early phase depending principally on the GI tract losses and secondarily on losses due to sepsis and fever. However, the GI tract losses can vary widely depending on the site of EAF. When fistula site is on the proximal jejunum, the fluid losses are important and so knowledge of GI fluids composition is necessary to effectively treat and prevent abnormalities [Table1].The development of PN was the most important advances made in the ECF management.The PN should be introduced as soon as the EAF diagnosis has been established and patient had been resuscitated and sepsis treated. The purpose of nutrition support is to meet the patient metabolic needs while a definitive management is planned [5,48]. The high fistula output and fluid losses from an open abdomen should be taken in consideration when calculating the patient nutrition needs. Up to 75 g/d of protein is normally absorbed by the small bowel [49]. The fluid loss from open abdomen contains up to 2 g of nitrogen per liter and so it should not be underestimated [49]. The calorie and protein needs may reach kcal/kg/d and 1.5–2.5 g/kg/d in case of a high-output fistula 30.However, care should be taken to avoid overfeeding consequences.Supplementation in copper, folic acid, vitamin B12 and C, and trace minerals may be necessary in patient with long-standing small-bowel fistulas [48].As shown, the spontaneous fistula closure rate was doubled after nutritional supplementation addition. [1,48,50] However, the heterogeneity of population involved in the studies and the predominance of the retrospective nature of these studies made more difficult to predictaccurately the timing and rate of spontaneous healing [1,48].As suggested by some studies, the fistula closure rates and mortality have been positively affected by PN [51] but until to date, there is no strong evidence that ECF closure is increased with PN alone [52]. Although in some cases, PN may be the only nutritional support that patient tolerates, enteral feeding is possible in large series of patient with ECF [53,54].

Enteral nutrition should be attempted once the fistula anatomy is defined and feasibility of enteral feeding is determined by the management team. The enteral nutrition is beneficial by preserving the mucosal barrier and immunologic function of the intestine resulting in decreasing infectious complications.The absolute contraindication to enteral nutrition is insufficient length (usually <75 cm) of usable bowel. The quality of the remaining small bowel is also important.The length of usable bowel can be difficult to estimate, however upper GI series, magnetic resonance enterography, and CT scan are useful to make a reasonable estimation. Enteral nutrition can be administrated by surgical tube-jejunostomy, passage of tube distal to fistula, and fistuloclysis.However, establishing an enteral feeding access can be difficult in some cases and teamwork perseverance is required

in these circumstances [5]. Fistuloclysis is a technique which consists of providing an enteral feeding through the fistula opening. The fistula effluent is collected from the proximal fistula limb and reinstalled into the distal limb. This is very useful to maintain fluid and electrolyte balance. fistuloclysis technique can be used to introduce an enteral nutrition by inserting a tube through the distal intestinal limb and the tube must be maintained in stable position avoiding migration and obstruction. Feeding a patient with EAF is reasonably started with standard polymeric formula. Exceptionally, if the usable bowel has a very short length less than 120cm, and patient does not tolerate the polymeric formula or experiences high fistula output, the patient should be switched to an elemental or semi elemental feed. As reported, the use of fistuloclysis with polymeric or elemental feeds resulted in patients with ECF resulted in the liberation of an important number of them from PN [55].

The introduction of Immunonutrition (glutamine) in critically ill surgical patients showed a reduction in infectious complications without effect on mortality [56]. Glutamine which is the primary nitrogen constitutes an energy source for the enterocyte and has a large effect on immune function and overall outcomes [56]. Glutamine has more pronounced positive effects when it is administered parenterally [57]. As reported, the combined use of oral glutamine with PN in high output fistula had been associated with accelerating healing and decreasing mortality without change in hospital stay length [58]. However, regarding the limit data in the EAF patients, the administration or oral glutamine in the hope to decrease overall inflammation and fistula effluent seems to be probably safe.

Table 1: Electrolyte Composition of Gastrointestinal Fluids.

Electrolyte (mEQ)	Na+	K+	Cl ⁻	HCO ₃ ⁻
Stomach	60–80	15	100	0
Bile	140	5–10	100	40
Small bowel	140	20	100	25–50
Large bowel	75	30	30	0

7.3 Medical treatment

Somatostatin is a hormone principally produced by the delta cells of the pancreas. Somatostatin and its analogues (octreotide) have an inhibitory properties including decrease of enteric secretions, suppression of gastrointestinal hormones, reducing of gastric emptying rate, and having a splanchnic vasoconstrictive effect [59,60]. Based on these inhibitory properties, the use of somatostatin has been advocated in the treatment of ECFs to reduce the fistula output volume [61]. Oppositely to somatostatin which has a short half-life (1–2 minutes) requiring continuous infusion [62], Octreotide is a longer-acting analogue with a half-life of 113 minutes allowing intermittent subcutaneous dosing and it's has a wide use in ECFs treating [61]. The efficacy of this

medication has been evaluated by measuring the impact on the fistula output volume, time to closure, and fistula closure rates. As demonstrated by investigations, both somatostatin and octreotide have an effective effect in decreasing the fistula output volume by as much as 40%–93% [60]. This reduction in output would be very beneficial in improving quality life and prognosis of patient with high output fistula volume by facilitating wound care and decrease damage to bowel and surrounding granulation tissue [60,62]. The combined use of TPN with somatostatin has a synergistic effect on the reduction of intestinal secretions and the improvement of fistula closure rates [60]. Several controlled trials demonstrated the significant improvement of these medications on the time to closure of ECFs [62–65]. On the other hand, most reports showed no effect on the actual rate of closure after use of somatostatin and its analogues [59,65]. This may be interpreted as a failure of conservative treatment which can be more likely related to fistula nature, such as its location, presence of distal obstruction, or malignancy. In addition, the octreotide can have an adverse effect on immune function and can reduce the splanchnic and portal blood flow [66], so care must be taken when using this medication. The use of Proton pump inhibitors and H₂ receptor antagonists did not show any positive effect on the fistula output and the spontaneous closure rate [3,10].

8. Reconstructive surgery

8.1 Timing of surgery

Defining the appropriate time to perform definitive reconstructive surgery for EAF after failure of conservative treatment is unclear in the absence of level I data supporting any specific period of delay. Timing of reconstructive surgery for EAF and AWR should be individualized according to patient characteristics. Softening of intra-abdominal adhesences, resolution of inflammatory processes and abdominal sepsis, achieving a best nutritional condition of patient, providing adequate wound care and reduction in the risk of bowel injury take more time usually longer than 3 months before conditions become ideal for surgery. Therefore, surgical judgment based on these multiple factors is likely the key to success. Longer time interval to surgery is associated with lower rates of fistula recurrence, morbidity and mortality [67–74]. So at least a waiting period of 6 months or longer after fistula formation is highly recommended by specialized center authors [71–74].

8.2 Fistula surgery

The risk factor that it can be modified is the surgical technique. Bowel resection was superior to over sewing and wedge repair, and complete resection of the affected intestinal segment was associated with lower rates of fistula recurrence [67,72,75]. The preferred anastomosis technique between stapled and hand-sewn

repair, the use of CST resulted in significant increase of the intra-abdominal volume without pulmonary compromise [84]. So restoring the lost domain may be possible after CST use without respiratory repercussions related to the loss of thoracic volume.

The major inconvenient of the anterior CST is large bilateral skin flaps resulting from necessary dissection for exposure and flap complications were the most wound matter noted in this procedure. The seroma and potential infection are common after performing anterior CST. The use of fibrin sealant has been shown to decrease seroma and wound infection rates [82]. Also eliminating the dead space by performing numerous “quilting” mattress sutures has been reported to reduce seroma formation. The use of minimally invasive technique has been described to achieve lateral release by creating small tunnels from the midline incision instead of large flaps [85]. Although the use of a large midline incision approach with avoiding to create a large flap with their attendant wound morbidity, this technique is ideal method for a single –stage repair of EAF [85]. Therefore, laparoscopic and minimally invasive approaches are likely useful to achieve a functional abdominal wall with avoiding morbidity related to extensive open procedures [86-88].

9. Summary

Enteroatmospheric fistula (EAF) is a feared and challenging complication for the clinical team. The open abdomen (OA) is associated with high risk of EAF formation. The multidisciplinary approach is the key of successful management. The principles treatment is based on the patient resuscitation, the elimination of an abdominal infection, the control of fistula effluent, the wound care and the introduction of nutritional support. The spontaneous healing of EAF is extremely rare and definitive surgery should be postponed until obtaining a best physical condition of patient. The abdominal wall reconstruction is a complex and high risk surgery. The abdominal wall repair can be staged or concomitantly performed with fistula surgery. Several factors may influence the determination of the appropriate wall closure approach. However, the prevention remains the best way to reduce the risks of EAF.

References

1. Sepehrpour S, Papagrigradiadis S. A systematic review of the benefit of total parenteral nutrition in the management of enterocutaneous fistulas. *Minerva Chir.* 2010; 65(5): 577–85.
2. Martinez JL, Luque-de-Leon E, Mier J. Systematic management of postoperative enterocutaneous fistulas: factors related to outcomes. *World J Surg.* 2008; 32(3): 436–43.
3. Draus JM Jr, Huss SA, Harty NJ. Enterocutaneous fistula: are treatments improving? *Surgery.* 2006; 140(4): 570–6.
4. Schechter WP. Management of enterocutaneous fistulas. *SurgClin North Am.* 2011; 91(3): 481–91.
5. Polk TM, Schwab CW. Metabolic and nutritional support of the enterocutaneous fistula patient: a three-phase approach. *World J Surg.* 2012; 36(3): 524–33.
6. Burch JM, Ortiz VB, Richardson RJ. Abbreviated laparotomy and planned reoperation for critically injured patients. *Ann Surg.* 1992; 215: 476-483.
7. Barker DE, Green JM, Maxwell RA. Experience with vacuum-pack temporary abdominal wound closure in 258 trauma and general and vascular surgical patients. *J Am Coll Surg.* 2007; 204: 784-792.
8. Miller RS, Morris JA Jr, Diaz JJ Jr. Complications after 344 damage control open celiotomies. *J Trauma.* 2005; 59(6): 1365-1374.
9. Teixeira PGR, Salim A, Inaba K. A prospective look at the current state of open abdomens. *Am Surg.* 2008; 74(10): 891-897.
10. Evenson AR, Fischer JE. Current management of enterocutaneous fistula. *J Gastrointest Surg.* 2006; 10(3): 455–64.
11. Fabian TC. Damage control in trauma: laparotomy wound management acute to chronic. *SurgClin North Am.* 2007; 87: 73-93.
12. Kritayakirana K, Maggio PM, Brundage S. Outcomes and complications of open abdomen technique for managing non-trauma patients. *J Emerg Trauma Shock.* 2010; 3(2): 118–22.
13. Schechter WP, Ivatury RR, Rotondo MF. Open abdomen after trauma and abdominal sepsis: a strategy for management. *J Am Coll Surg.* 2006; 203(3): 390–6.
14. Prichayudh S, Sriussadaporn S, Samorn P. Management of open abdomen with an absorbable mesh closure. *Surg Today.* 2011; 41(1): 72–8.
15. Stevens P. Vacuum-assisted closure of laparostomy wounds: a critical review of the literature. *Int Wound J.* 2009; 6(4): 259–66.
16. Shaikh IA, Ballard-Wilson A, Yalamarthy S. Use of topical negative pressure in assisted abdominal closure does not lead to high incidence of enteric fistulae. *Colorectal Dis.* 2010; 12(9): 931–4.
17. Bee TK, Croce MA, Magnotti LJ. Temporary abdominal closure techniques: a prospective randomized trial comparing polyglactin 910 mesh and vacuum assisted closure. *J Trauma.* 2008; 65(2): 337–42.
18. Scott BG, Welsh FJ, Pham HQ. Early aggressive closure of the open Abdomen. *J Trauma.* 2006; 60(1): 17–22.
19. Blatnik J, Jin J, Rosen M. Abdominal hernia repair with bridging acellular dermal matrix - an expensive hernia sac. *Am J Surg.* 2008; 196: 47–50.

20. De Moya M, Dunham M, Inaba K. Long-term outcome of acellular dermal matrix when used for large traumatic open abdomen. *J Trauma*. 2008; 65: 349–53.
21. Hedderich GS, Wexler MJ, McLean AP. The septic abdomen: open management with Marlex mesh with a zipper. *Surgery*. 1986; 99(4): 399–408.
22. Acosta S, Bjarnason T, Petersson U. Multicentre prospective study of fascial closure rate after open abdomen with vacuum and mesh-mediated fascial traction. *Br J Surg*. 2011; 98(5): 735–43.
23. Koss W, Ho HC, Yu M. Preventing loss of domain: a management strategy for closure of the “open abdomen” during the initial hospitalization. *J Surg Educ*. 2009; 66(2): 89–95.
24. Vertrees A, Greer L, Pickett C. Modern management of complex open abdominal wounds of war: a 5-year experience. *J Am Coll Surg*. 2008; 207(6): 801–9.
25. Kafie FE, Tessier DJ, Williams RA. Serial abdominal closure technique (the “SAC” procedure): a novel method for delayed closure of the abdominal wall. *Am Surg*. 2003; 69(2): 102–5.
26. Schechter WP, Hirshberg A, Chang DS. Enteric fistulas: principles of management. *J Am Coll Surg*. 2009; 209(4): 484–491.
27. Hatch QM, Osterhout LM, Podbielski J. Impact of closure at the first take back: complication burden and potential overutilization of damage control laparotomy. *J Trauma*. 2011; 71(6): 1503–1511.
28. Collier B, Guillaumondegui O, Cotton B. Feeding the open abdomen. *JPEN J Parenter Enteral Nutr*. 2007; 31(5): 410–5.
29. Fazio VW. Intestinal fistula. *Atlas of colorectal surgery*. New York: Churchill Livingstone;1996. p. 363–77.
30. Lynch AC, Delaney CP, Senagore AJ. Clinical outcome and factors predictive of recurrence after enterocutaneous fistula surgery. *Ann Surg*. 2004; 240(5): 825–31.
31. Wright A, Wright M. Bedside management of an abdominal wound containing an enteroatmospheric fistula: a case report. *Ostomy Wound Manage*. 2011; 57(1): 28–32.
32. Ramsay PT, Mejia VA. Management of enteroatmospheric fistulae in the open abdomen. *Am Surg*. 2010; 76(6): 637–9.
33. Layton B, Dubose J, Nichols S. Pacifying the open abdomen with concomitant intestinal fistula: a novel approach. *Am J Surg*. 2010; 199(4): e48–50.
34. Al-Khoury G, Kaufman D, Hirshberg A. Improved control of exposed fistula in the open abdomen. *J Am Coll Surg*. 2008; 206(2): 397–8.
35. O’Brien B, Landis-Erdman J, Erwin-Toth P. Nursing management of multiple enterocutaneous fistulae located in the center of a large open abdominal wound: a case study. *Ostomy Wound Manage*. 1998; 44(1): 20–4.
36. Girard S, Sideman M, Spain DA. A novel approach to the problem of intestinal fistulization arising in patients managed with open peritoneal cavities. *Am J Surg*. 2002; 184: 166–167.
37. Sarfeh IJ, Jakowatz JG. Surgical treatment of enteric ‘bud’ fistulas in contaminated wounds: a riskless extraperitoneal method using split-thickness skin grafts. *Arch Surg*. 1992; 127: 1027–1030.
38. Subramaniam MH, Liscum KR, Hirshberg A. The floating stoma: a new technique for controlling exposed fistulae in abdominal trauma. *J Trauma*. 2002; 53: 386–388.
39. Di Saverio S, Villani S, Biscardi A. Open abdomen with concomitant enteroatmospheric fistula: validation, refinements, and adjuncts to a novel approach. *J Trauma*. 2011; 71(3): 760–762.
40. Cro C, George KJ, Donnelly J, et al. Vacuum assisted closure system in the management of enterocutaneous fistulae. *Postgrad Med*. 2002; 78: 354–355.
41. Goverman J, Yelon JA, Platz JJ. The “fistula-VAC,” a technique for management of enterocutaneous fistulae arising within the open abdomen: a report of 5 cases. *J Trauma*. 2006; 60(2): 428–31.
42. Derek J, Roberts D, David A. Negative-pressure wound therapy for critically ill adults with open abdominal wounds: A systematic review. *J Trauma Acute Care Surg*. 2012; 73: 629–39.
43. Roberto Cirocchi, Arianna Birindelli, Walter L. Biffl. What is the effectiveness of the negative pressure wound therapy (NPWT) in patients treated with open abdomen technique? A systematic review and meta-analysis. *J Trauma Acute Care Surg*. 2016; 81: 575–584.
44. Harris C, Shannon R. An innovative enterostomal therapy nurse model of community wound care delivery: a retrospective cost-effectiveness analysis. *J Wound Ostomy Continence Nurs*. 2008; 35(2): 169–83.
45. Boulanger K, Lemaise V, Jacquemin D. Vacuum-assisted closure of enterocutaneous fistula. *ActaChir Belg*. 2007; 107: 703–705.
46. Berry SM, Fischer JE. Enterocutaneous fistulas. *CurrProbl Surg*. 1994; 31(6): 469–566.
47. Makhdoom ZA, Komar MJ, Still CD. Nutrition and enterocutaneous fistulas. *J ClinGastroenterol*. 2000; 31(3): 195–204.
48. Dudrick SJ, Maharaj AR, McKelvey AA. Artificial nutritional support in patients with gastrointestinal fistulas. *World J Surg*. 1999; 23: 570–576.
49. Cheatham ML, Safcsak K, Brzezinski SJ. Nitrogen balance, protein loss, and the open abdomen. *Crit Care Med*. 2007; 35(1): 127–131.

50. Sitges-Serra A, Jaurrieta E, Sitges-Creus A. Management of postoperative enterocutaneous fistulas: the roles of parenteral nutrition and surgery. *Br J Surg*. 1982; 69(3): 147–50.
51. Meguid MM, Campos AC. Nutritional management of patients with gastrointestinal fistulas. *SurgClin North Am*. 1996; 76: 1035-1080.
52. Lloyd DAJ, Gabe SM, Windsor ACJ. Nutrition and management of enterocutaneous fistulas. *Br J Surg*. 2006; 93: 1045-1055.
53. Li J, Ren J, Zhu W. Management of enterocutaneous fistulas: 30-year experience. *Chin Med J (Engl)*. 2003; 116: 171-175.
54. Levy E, Frileux P, Cugnenc PH. High-output external fistulae of the small bowel: management with continuous enteral nutrition. *Br J Surg*. 1989; 76: 676-679.
55. Teubner A, Morrison K, Ravishakar HR. Fistuloclysis can successfully replace parenteral feeding in the nutritional support of patients with enterocutaneous fistulas. *Br J Surg*. 2004; 91: 625-631.
56. Newsholme P. Why is L-glutamine metabolism important to cells of the immune system in health, postinjury, surgery, or infection? *J Nutr*. 2001; 131(suppl): 2515S-2522S.
57. Novak F, Heyland DK, Avenell A. Glutamine supplementation in serious illness: a systematic review of the evidence. *Crit Care Med*. 2002; 30: 2022-2029.
58. De Agular-Nascimento JE, Caporossi C, Dock-Nascimento DB. Oral glutamine in addition to parenteral nutrition improves mortality and the healing of high-output intestinal fistulas. *Nutr Hosp*. 2007; 22(6): 672-676.
59. Hesse U, Ysebaert D, de Hemptinne B. Role of somatostatin-14 and its analogues in the management of gastrointestinal fistulae: clinical data. *Gut* 2001; 49(Suppl 4): iv11–21.
60. Di Costanzo J, Cano N, Martin J. Treatment of external gastrointestinal fistulas by a combination of total parenteral nutrition and somatostatin. *JPEN J Parenter Enteral Nutr*. 1987; 11(5): 465–70.
61. Sheppard M, Shapiro B, Pimstone B. Metabolic clearance and plasma half-disappearance time of exogenous somatostatin in man. *J Clin Endocrinol Metab*. 1979; 48(1): 50–3.
62. Torres AJ, Landa JJ, Moreno-Azcoita M. Somatostatin in the management of gastrointestinal fistulas. A multicenter trial. *Arch Surg*. 1992; 127(1): 97–9
63. Emory RE Jr, Ilstrup D, Grant CS. Somatostatin in the management of gastrointestinal fistulas. *Arch Surg*. 1992; 127(11): 1365.
64. Sancho JJ, di Costanzo J, Nubiola P. Randomized double-blind placebo controlled trial of early octreotide in patients with postoperative enterocutaneous fistula. *Br J Surg*. 1995; 82(5): 638–41.
65. Hernandez-Aranda JC, Gallo-Chico B, Flores-Ramirez LA. Treatment of enterocutaneous fistula with or without octreotide and parenteral nutrition. *Nutr Hosp*. 1996; 11(4): 226–9.
66. Cooper AM, Braatvedt GD, Brown H. Fasting and post-prandial splanchnic blood flow is reduced by a somatostatin analogue (octreotide) in man. *ClinSci (Lond)*. 1991; 81(2): 169-175.
67. Owen RM, Love TP, Perez SD. Definitive surgical treatment of enterocutaneous fistula: outcomes of a 23-year experience. *JAMA Surg*. 2013; 148: 118–126.
68. Martinez JL, Luque-de-Leon E, Ballinas-Oseguera G. Factors predictive of recurrence and mortality after surgical repair of enterocutaneous fistula. *J Gastrointest Surg*. 2012; 16:156–163.
69. Visschers RG, OldeDamink SW, Winkens B. Treatment strategies in 135 consecutive patients with enterocutaneous fistulas. *World J Surg*. 2008; 32: 445–453.
70. Wainstein DE, Sisco P, Deforel ML. Systematic and specific treatment of patients with enteroatmospheric fistulas: from initial conservative treatment to definitive surgery. *SurgTechnol Int*. 2016; 28: 73–81.
71. Brenner M, Clayton JL, Tillou A. Risk factors for recurrence after repair of enterocutaneous fistula. *Arch Surg*. 2009; 144: 500–505.
72. Ravindran P, Ansari N, Young CJ. Definitive surgical closure of enterocutaneous fistula: outcome and factors predictive of increased post-operative morbidity. *Colorectal Dis*. 2014; 16: 209–218.
73. Datta V, Engledow A, Chan S. The management of enterocutaneous fistula in a regional unit in the United Kingdom: a prospective study. *Dis Colon Rectum*. 2010; 53: 192–199.
74. Boukerrouche A. Postponed Reconstructive Surgery for Entero-Cutaneous Fistulas. *Journal of Surgery. Jurnalul de chirurgie*. 2018; 14(3): 91-93 DOI: 10.7438/1584-9341-14-3-93.
75. Slater NJ, Bokkerink WJ, Konijn V. Safety and durability of 1-stage repair of abdominal wall defects with enteric fistulas. *Ann Surg*. 2014; 261: 553–557.
76. Ewart CJ, Lankford AB, Gamboa MG. Successful closure of abdominal wall hernias using components separation technique. *Ann Plast Surg*. 2003; 50: 269–74.
77. Ramirez OM, Ruas E, Dellon L. “Components separation” method for closure of abdominal-wall defects: an anatomic and clinical study. *PlastReconstr Surg*. 1990; 86: 519–26.
78. De VriesReilingh TS, van Goor H, Charbon JA. Repair of giant midline abdominal wall hernias: “components separation technique” versus

prosthetic repair. *World J Surg.* 2007; 31: 756–63.

79. Dragu A, Klein P, Unglaub F. Tensiometry as a decision tool for abdominal wall reconstruction with component separation. *World J Surg.* 2009; 33: 1174–80.

80. Lowe JB, Lowe JB, Baty JD. Risks associated with “components separation” for closure of complex abdominal wall defects. *Plast Reconstr Surg.* 2003; 111: 1276–83.

81. Carbonell AM, Cobb WS, Chen SM. Posterior components separation during retromuscular hernia repair. *Hernia.* 2008; 12: 359–62.

82. Kingsnorth AN, Shahid MK, Valliattu AJ. Open onlay mesh repair for major abdominal wall hernias with selective use of components separation and fibrin sealant. *World J Surg.* 2008; 32: 26–30.

83. De VriesReilingh TS, van Goor H, Rosman C. “Components separation technique” for the repair of large abdominal wall hernias. *J Am Coll Surg.* 2003; 196: 32–7.

84. Hadad I, Small W, Dumanian GA. Repair of massive ventral hernias with the separation of parts technique: reversal of the ‘lost domain’. *Am Surg.* 2009; 75: 301–6.

85. Maas SM, van Engeland M, Leeksa NG. A modification of the “components separation” technique for closure of abdominal wall defects in the presence of an enterostomy. *J Am Coll Surg.* 1999; 189: 138–40.

86. Rosen MJ, Jin J, McGee MF. Laparoscopic component separation in the single-stage treatment of infected abdominal wall prosthetic removal. *Hernia.* 2007; 11: 435–40.

87. Rosen MJ, Williams C, Jin J. Laparoscopic versus open-component separation: a comparative analysis in a porcine model. *Am J Surg.* 2007; 194: 385–9.

88. Milburn ML, Shah PK, Friedman EB. Laparoscopically assisted components separation technique for ventral incisional hernia repair. *Hernia* 2007; 11: 157–61.